

Sexual Dimorphism in Osteometric Indices of Kuri Cattle Skulls

B. G. Gambo¹, A. Yahaya¹, M. B. Abdulhamid² and J. O. Olopade*³

¹ Department of Veterinary Anatomy, University of Maiduguri, Maiduguri, Nigeria. ² Department of Medical Laboratory Sciences, University of Maiduguri, Maiduguri, Nigeria. ³ Department of Veterinary Anatomy, University of Ibadan, Ibadan, Nigeria.

Summary: This work investigated 30 skulls of the Kuri cattle comprising 15 males and 15 females, of three age groups, 10 young (9 months to less than 3 years), 10 middle aged (3 to 5 years) and 10 aged (greater than 5 years). The skulls were prepared using hot water maceration technique. Using Ruler, thread and divider; 59 Osteometric parameters were taken to determine sexual dimorphism, only 6 indices showed statistically significant differences between the sexes. These indices were maximum intercondylar width (MICW), right supraorbital foramen to interfrontal suture (ISRSOF), left supraorbital foramen to interfrontal suture (ISLSOF), lateral intercornual length (LICL), intertemporal line width (ITLW) and horn base circumference (HBC). The female had longer viscerocranial length (VCrL) both on the nasal and palatal aspects, but were wider in the male. The male had longer and wider neurocranium. The paracondylar process length (PCPL) was longer in the female, but the male had wider interparacondylar width (IPCW) and maximum intercondylar width (MICW) While the ISRSOF significant difference appeared only at the middle-age group at $p < 0.05$, the ISLSOF did not differ significantly at any particular age group but only overall mean of all the three age groups ($n=15$) presented the difference significantly. The MICW showed significant difference ($p < 0.05$) at two age groups; young and the middle-age. The LICL and ITLW values are highly significant ($p < 0.01$) and the HBC value was also significant ($p < 0.05$) all at the middle age. No significant difference was recorded between the two sexes in the aged Kuri cattle; indicating that the female tends to progressively increase in size beyond 5 years old thereby making these values insignificant from the male counterpart at old age. In conclusion, the middle-age Kuri cattle have the most sexually dimorphic osteometric landmarks in the skull with the male having higher values than the female. This data will be useful for anatomical, developmental, anthropological forensic and clinical studies, and form basis for comparison with other breeds of cattle.

Keywords: Osteometry, Kuri cattle, Skull, Age, Sex dimorphism

©Physiological Society of Nigeria

*Address for correspondence: jkayodeolopade@yahoo.com

Manuscript Accepted: December, 2019

INTRODUCTION

The Kuri (White lake cattle or Buduma) is a breed of cattle found mainly on the Islands and along the shore of the Lake Chad, formed by the four neighbouring countries of Nigeria, Niger, Cameroon and Chad considered to be the area of origin of the breed (Malbrant *et al.* 1947a and Malbrant *et al.* 1947b). The Kuri breed is of the Hamitic long horn (*Bos taurus longifrons*). The actual population of Kuri cattle has never been precisely known, however, several authors put the worldwide estimate within the range of one hundred to four hundred thousand (Tawah *et al.* 1997). The Kuri breed is an imposing breed, whose size is rarely seen in African cattle with well-developed bones (Epstein, 1971). The typical characteristic of the Kuri is the disproportionate large horns that draw immediate attention, coupled with the lack of a hump adds to the compact appearance of the Kuri cattle. Its height and size contribute to the average weight of

550kg, but under feedlot, can reach up to 600-700kg. (Epstein, 1971; Queval *et al.* 1971).

Sexual dimorphism in skulls of different animal species is of importance in anatomic, archaeological and forensic studies (Bornholdt *et al.* 2008). Even though classical differences can be observed phenotypically in the skull of some species between sexes (Yahaya *et al.* 2012a), this can be marginal in some. This requires precise morphometric analyses to differentiate them (Mazak, 2004).

Studies have been carried out on the Kuri cattle in the area of production and distribution (Epstein, 1971; Malbrant *et al.* 1947a and b; Tawah *et al.* 1997), dental abnormalities (Gambo *et al.*, 2015a), mandibular and maxillofacial regions (Gambo *et al.* 2015b; Gambo *et al.* 2016). In our continuous effort to document the anatomy of the skull of Kuri cattle, in this work we studied the different osteometric indices in the skull of Kuri cattle and report herein the skull osteometric indices of the male and female Kuri cattle.

MATERIALS AND METHODS

A total of thirty (30) Kuri cattle consisting of 15 males and females each were used for this study. The breed was identified by their typical characteristics such as the disproportionate large horns, coupled with the lack of a hump and color. This included 10 young Kuri cattle between the ages of 9 months to less than 3 years, 10 middle-aged between the ages of 3 to 5 years old, and 10 Aged Kuri cattle greater than 5 years all consisting of 5 male and female in each group. The animals were physically examined for their state of health particularly for absence of musculoskeletal deformities, and age was estimated based on dental eruption technique as described by Pasquini (1982). Sex of each animal was determined by physical observation of the perineum and inguinal areas. The heads were obtained immediately after slaughter from Shomolu Bariga, Bodija, Ijebu-Igbo and Maiduguri Main abattoirs of Lagos, Oyo, Ogun and Borno states of Nigeria respectively. The skulls were prepared according to the hot water maceration technique described by Olopade and Onwuka (2005), Yahaya *et al.* (2012b) and Gambo *et al.* (2015b). A digital camera with 16 megapixels lens was used in the production of figures in this study.

A total of 59 osteometric parameters were obtained on each skull with the aid of metric rules, vernier calipers, threads and a pair of dividers and compasses and depicted in figures 1-5. Morphometric parameters were adopted from the works of Olopade and Onwuka (2005) and Yahaya *et al.* (2012b). Vital landmarks were produced to fit this species/breed.

Osteometric measurements and indices

1. Incisive – Nuchal length (**INL**): Maximum dimensions of the skull when laid on an even surface from the rostral tip of the incisive bone to the caudal level of the nuchal protuberance.
2. Supraorbital width (**SOBW**): Maximum distance between the dorsomedial edges of the orbit at the frontal bone.
3. Intermedial canthi length (**IMCL**): Distance between the two medial canthi.
4. Interlateral canthi length (**ILCL**): Distance between the two lateral canthi.
5. Interfrontal suture length (**IFSL**): Maximum length of the interfrontal suture.
6. Interfrontal suture to right supraorbital foramen (**ISRSOF**): Distance between right supraorbital foramen to interfrontal suture directed medial.
7. Interfrontal suture to left supraorbital foramen (**ISLSOF**): Distance between left supraorbital foramen to interfrontal suture directed medial.
8. Intercornual protuberance to line of intersection of Right (**ICPLIR**): Distance between intercornual protuberance to line of intersection.
9. Intercornual protuberance to line of intersection of left (**ICPLIL**): Distance between intercornual protuberance to line of intersection of 5 above.
10. Nasal length at midline (**NLM**): Maximum length of nasal bone along the midline.
11. Nasal length at lateral prongs (**NLLP**): Maximum length of nasal bone at the level of the lateral nasal prongs.
12. Nasal width (**NW**): Maximum width of the two nasal bones.
13. Viscerocranial length (**VCrL**): Maximum distance from nasofrontal suture to the rostral end of the interincisive suture along the median plane.
14. Interpalatine suture length 1 (**IPSL1**): Maximum length of the horizontal parts of palatine at the suture.
15. Interpalatine suture length 2 (**IPSL2**): Maximum length of the horizontal parts of palatine process of the maxilla at the suture.
16. Interpalatine suture length (**IPSLM**): Maximum length of the horizontal parts of palatine and palatine process of maxilla at the suture.
17. Interincisive suture length (**IISL**): Maximum distance from mid-rostral tip of the incisive bone to the incisive-maxillary junction at the palatal surface.
18. Left Incisive fissure length (**LIFL**): Maximum rostro-caudal distance of the incisive fissure.
19. Right Incisive fissure length (**RIFL**): Maximum rostro-caudal distance of the incisive fissure.
20. Left Incisive fissure width (**LIFW**): Maximum width of the incisive fissure.
21. Right Incisive fissure width (**RIFW**): Maximum width of the incisive fissure.
22. Hard palate length (**HPL**): Maximum distance at the midline of the caudal end of hard palate to the most rostral margin of the incisive bone.
23. Palatine width at premolar 1 (**PWP1**): width between the median aspects of alveoli at premolar one.
24. Palatine width at molar 1 (**PWM1**): width between the median aspects of alveoli at molar one.
25. Palatine width at molar 3 (**PWM3**): width between the median aspects of alveoli at molar three.
26. Choana length (**ChL**): Distance between the basisphenoid to the most caudal margin of the hard palate.
27. Choana width 1 (**ChW1**): Distance between the medial margins of the two pterygoid crests.
28. Choana width 2 (**ChW2**): Distance between the medial margins of the pterygoid hamulus.
29. Maximum zygomatic width 1 (**MZW1**): Maximum distance between the zygomatic arches at the level of the orbit.
30. Maximum zygomatic width 2 (**MZW2**): Maximum distance between the zygomatic

- arches at junction of zygomatic process of temporal bone and temporal process of zygomatic bone.
31. Incisivo-occipital length (**IOL**): Maximum distance between the most rostral end of the incisive and caudal limits of the external occipital protuberance.
 32. Condylobasal length (**CBL**): Length of the skull measured from the caudal surface of the occipital condyles to the rostral tip of the incisive bones.
 33. Intercornual Protuberance to Foramen magnum (**IPFM**): Distance between intercornual protuberance to dorsal brim of foramen magnum at the midline.
 34. Foramen magnum height (**FMH**): Mid-vertical height of the foramen magnum.
 35. Foramen magnum width (**FMW**): Width of the foramen magnum at the median protuberance of the two condyles in to the foramen magnum.
 36. Foramen magnum circumference (**FMC**): length of the foramen magnum circumference.
 37. Foramen magnum Index (**FMI**): $\frac{EMH \times 100}{FMW}$
 38. Maximum intercondylar width (**MICW**): Maximum distance between the two occipital condyles at the caudal surface.
 39. Interjugular process width (**IJPW**): Maximum distance between the tips of the two jugular processes.
 40. Paracondylar process length (**PCPL**): Distance between tips of the paracondylar (jugular) process directly to its junction with squamous occipital bone.
 41. Interparacondylar width (**IPCW**): The widest breath between the most lateral ends of the paracondylar process.
 42. Whole skull height 1 (**WSH1**): Distance between the most ventral part of the skull (without mandible) and the highest point of the skull when laid on an even surface.
 43. Whole skull height 2 (**WSH2**): Distance between the most ventral part of the skull (without mandible) to the intercornual protuberance.
 44. Skull height (**SH**): Distance between the highest point of the skull (intercornual protuberance) and the base of the mandible.
 45. Intercornual protuberance to external occipital protuberance (**IPEOP**): Contour length of the distance between the Intercornual protuberance to external occipital protuberance.
 46. Neurocranial volume (**NCV**): The volume of the neurocranium in milliliters. Measured by blocking all the foramina (with fresh plasticine) leading to the neurocranium except the foramen magnum. The neurocranium was then filled with fine quality millet grains, which was then emptied into a measuring cylinder to determine the volume.
 47. Medial intercornual length (**MICL**): Distance between the two cornual processes at the fronto-cornual junction.
 48. Lateral intercornual length (**LICL**): Distance between the two lateral edges of the fronto-cornual junction.
 49. Left horn curvature length rostral (**LHCLR**): maximum curvature length of the left horn at the rostral surface.
 50. Right horn curvature length rostral (**RHCLR**): maximum curvature length of the right horn at the rostral surface.
 51. Left horn curvature length caudal (**LHCLC**): maximum curvature length of the left horn at the caudal surface.
 52. Right horn curvature length caudal (**RHCLC**): maximum curvature length of the right horn at the caudal surface.
 53. Left horn curvature length medial (**LHCLM**): maximum curvature length of the left horn at the medial surface.
 54. Right horn curvature length medial (**RHCLM**): maximum curvature length of the right horn at the medial surface.
 55. Left horn curvature length lateral (**LHCLL**): maximum curvature length of the left horn at the lateral surface.
 56. Right horn curvature length lateral (**RHCLL**): maximum curvature length of the right horn at the lateral surface.
 57. Intercornual tip width (**ICTW**): Distance between the tips of the two horns.
 58. Intertemporal line width (**ITLW**): Distance between the two temporal lines at the frontal bone.
 59. Horn base circumference (**HBC**): Length of circumference of the base of the horn.

Statistical Analysis

Mean values and standard deviation were obtained for each parameter; independent student *t* test was used to analyze gender difference between groups using SPSS software package.

RESULTS

The osteometric data obtained for males and females Kuri cattle are shown in Tables 1-4. In this study, only 6 out of the 59 skull parameters taken showed statistical significance. ISRSOF, HBC, MICW were significant ($p < 0.05$) between sexes, while LICL and ITLW were highly significant ($p < 0.01$) all at the middle age, but MICW is also significant at young age $p < 0.05$ (Table 5). The overall mean ($n = 15$ for each sex) of ISLSOF was significant ($p < 0.05$), but did not show any significance at particular age group. The values of the nasal length (NLM and NLLP) and viscerocranium are higher in the female, but the nasal width (NW) is higher in the male. The neurocranial

Table 1- Skull measures and indices of the of Kuri cattle (appreciable from a Dorsal view)

Measurements (cm)	Male	Female
INL	50.38 ± 6.75	49.87 ± 4.75
SOBW	15.96 ± 1.88	14.71 ± 1.50
IMCL	14.97 ± 2.34	14.87 ± 1.74
ILCL	22.10 ± 2.52	20.53 ± 2.04
IFSL	23.63 ± 3.10	22.53 ± 2.17
ISRSOF	6.81 ± 9.12	5.83 ± 0.68*
ISLSOF	6.86 ± 0.05	5.94 ± 0.73*
ICPLIR	12.40 ± 1.98	12.88 ± 1.80
ICPLIL	12.47 ± 1.99	13.03 ± 1.61
NLM	18.59 ± 2.31	18.85 ± 2.45
NLLP	18.29 ± 2.46	18.70 ± 2.04
NW	6.29 ± 0.78	5.88 ± 0.77
VChL	25.75 ± 2.92	26.01 ± 2.57

*Mean difference is significant at p<0.05

Table 2- Skull measures and indices of the of Kuri cattle (appreciable from a ventral view)

Measurements (cm)	Male	Female
IPSL1	6.95 ± 1.14	6.64 ± 0.91
IPSL2	9.63 ± 1.27	10.11 ± 1.21
IPSLM	16.58 ± 2.05	16.75 ± 1.81
IISL	10.66 ± 1.24	10.75 ± 1.14
LIFL	6.70 ± 0.70	6.37 ± 0.58
RIFL	6.71 ± 0.71	6.36 ± 0.56
LIFW	1.63 ± 0.20	1.57 ± 0.50
RIFW	1.65 ± 0.25	1.54 ± 0.12
HPL	27.24 ± 2.83	27.50 ± 2.43
PWP1	6.77 ± 0.99	6.95 ± 0.84
PWM1	7.94 ± 0.98	7.89 ± 0.86
PWM3	7.67 ± 0.93	7.59 ± 0.61
ChL	10.52 ± 1.42	10.10 ± 0.94
ChW1	3.30 ± 0.44	3.51 ± 0.43
ChW2	3.08 ± 0.46	3.00 ± 0.53
MZW1	19.95 ± 2.19	18.78 ± 1.46
MZW2	19.13 ± 1.74	18.37 ± 1.15
IOL	47.87 ± 4.61	46.83 ± 3.23
CBL	47.07 ± 4.16	46.62 ± 3.26

Table 5- Age related sex dimorphic indices in Kuri cattle.

Paramet. (cm)	Young		Middle-age		Aged	
	Male	Female	Male	Female	Male	Female
ISRSOF	6.24±0.37	5.74±0.24	7.10±0.36*	5.72±0.40	7.10±0.44	6.02±0.31
ISLSOF	6.32±0.40	5.86±0.31	7.06±0.40	5.84±0.43	7.20±0.58	6.12±0.28
MICW	10.26±0.23*	9.14±0.39	11.04±0.16*	10.42±0.12	11.32±0.53	10.40±0.24
LICL	23.78±1.11	22.42±1.25	26.96±0.61**	22.28±0.55	27.22±2.65	25.46±1.00
ITLW	19.06±0.81	17.0±0.56	21.38±0.42**	18.24±0.49	21.60±1.32	18.98±0.55
HBC	30.92±1.44	27.08±3.06	42.90±1.45*	33.10±2.50	44.84±5.32	38.08±2.12

** Mean difference is significant at p<0.01, *Mean difference is significant at p<0.05

length (IFSL) and width (IMCL, SOBW and ILCL) is higher in the male but not significant. All the parameters obtained on the ventral aspect of the skull were not significant. The overall hard palate length (HPL), the perpendicular palatine (IPSL2), the Choana width at the pterygoid crest (ChL1) and the interincisive suture are higher in the female, but the palatine process of the maxilla is longer in the male. The Choana length (ChL), choana width at the

Table 3- Skull measures and indices of the of Kuri cattle (appreciable from caudal and occipital view)

Measurements (cm)	Male	Female
IPFM	10.43 ± 1.23	10.13 ± 0.67
FMH	3.95 ± 0.32	3.97 ± 0.32
FMW	3.63 ± 0.34	3.85 ± 0.38
FMC	13.75 ± 1.16	13.55 ± 0.74
FMI ^{oo}	109.23 ± 10.88	103.70 ± 11.31
MICW	10.87 ± 0.85	9.99 ± 0.84*
IJPW	8.26 ± 1.47	8.17 ± 0.88
PCPL	6.01 ± 0.72	6.17 ± 0.54
IPCW	15.35 ± 1.76	14.88 ± 1.34
WSH1	18.38 ± 2.17	17.51 ± 1.51
WSH2	16.07 ± 1.61	15.43 ± 1.25
SH	27.05 ± 3.05	26.69 ± 2.24
IPEOP	9.21 ± 1.13	8.42 ± 1.00
NCV _{ml}	496.47 ± 68.48	459.60 ± 29.94

*Mean difference is significant at p<0.05, ml= millilitres, oo = Parameter without unit

Table 4: Skull measures and indices of the of Kuri cattle (appreciable from frontal and caudal skull view)

Parameters (cm)	Male	Female
MICL	11.54 ± 1.60	12.45 ± 1.87
LICL	25.99 ± 3.86	23.39 ± 2.53*
LHCLR	55.50 ± 22.77	48.85 ± 21.79
RHCLR	55.55 ± 22.74	49.25 ± 21.55
LHCLC	62.21 ± 24.33	54.83 ± 24.53
RHCLC	62.26 ± 24.39	55.09 ± 24.17
LHCLM	55.69 ± 21.61	49.57 ± 21.10
RHCLM	55.53 ± 21.28	49.83 ± 20.82
LHCLL	60.53 ± 23.97	53.17 ± 23.86
RHCLL	60.48 ± 23.51	49.46 ± 24.28
ICTW	65.55 ± 20.78	65.07 ± 21.89
ITLW	20.68 ± 2.25	18.07 ± 1.40*
HBC	39.55 ± 9.33	32.75 ± 7.10*

*Mean difference is significant at p<0.05

pterygoid hamulus (ChL2), Incisivo-occipital length (IOL), condylobasal length and maximum zygomatic width (MZW1 and MZW2) values are higher in the male. Values of the width of hard palate at molar 1 and molar 3 (PWM1 and PWM3) are higher in the male, but at premolar 1 (PWP1) is higher in the female, though. The values of the incisive fissure lengths and widths (RIFL, LIFL, RIFW and LIFW) are bilaterally higher in the male (Table 2).

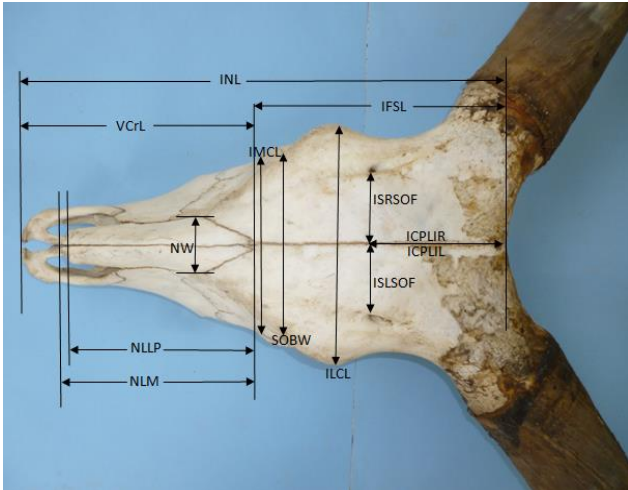


Figure 1: Measurements of the Kuri cattle skull (dorsal view) showing Incisive – Nuchal length (INL), Supraorbital width (SOBW), Intermedial canthi length (IMCL), Interlateral canthi length (ILCL), Interfrontal suture length (IFSL), Interfrontal Suture to right supraorbital foramen (ISRSOF), Interfrontal Suture to left supraorbital foramen (ISLSOF), Intercornual protuberance to line of intersection of Right (ICPLIR), Intercornual protuberance to line of intersection of left (ICPLIL), Nasal length at midline (NLM), Nasal length at lateral prongs (NLLP), Nasal width (NW), and Viscerocranial length (VCrL).

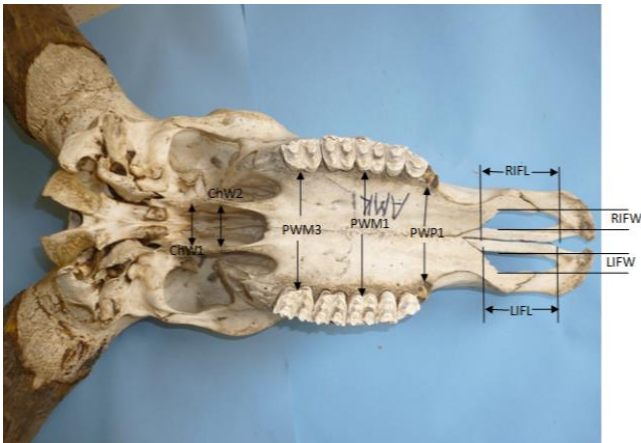


Figure 2: Measurements of the Kuri cattle skull without mandible (ventral view) showing Left Incisive fissure length (LIFL), Right Incisive fissure length (RIFL), Left Incisive fissure width (LIFW), Right Incisive fissure width (RIFW), Palatine width at premolar 1 (PWP1), Palatine width at molar 1 (PWM1), Palatine width at molar 3 (PWM3), Choana width 1 (ChW1), and Choana width 2 (ChW2).

On the occipital and caudal aspects of the skull, only the maximum intercondylar (MICW) value showed statistical significance where the male recorded higher value, but all the other values were not significant. However, the intercornual protuberance to external occipital protuberance (IPEOP), Intercornual protuberance to foramen magnum (IPFM), interjugular process width (IJPW), interparacondylar width (IPCW), whole skull height (WSH1 and

WSH2), and neurocranial volume (NCV) were also higher in the male. The foramen magnum height (FMH), foramen magnum width (FMW) and paracondylar process length (PCPL) values were higher in the female. Bilaterally, all the horn parameters taken on the rostral, caudal, lateral and medial aspects showed higher values in the male that were not significant, but the horn base circumference (HBC) value of the male was significantly higher.

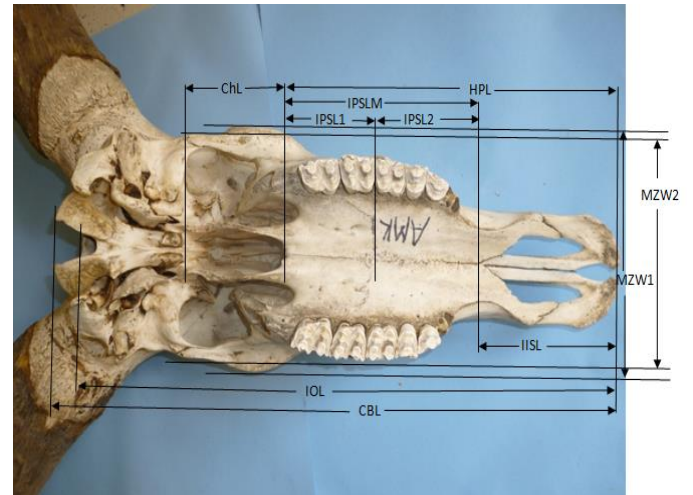


Figure 3: Measurements of the Kuri cattle skull without mandible (ventral view) showing Hard palate length (HPL), Choana length (ChL), Maximum zygomatic width 1 (MZW1), Maximum zygomatic width 2 (MZW2), Interincisive suture length (IISL), Interpalatine suture length 1 (IPSL1), Interpalatine suture length 2 (IPSL2), Interpalatine suture length (IPSLM), Incisivo-occipital length (IOL), and Condylbasal length (CBL).

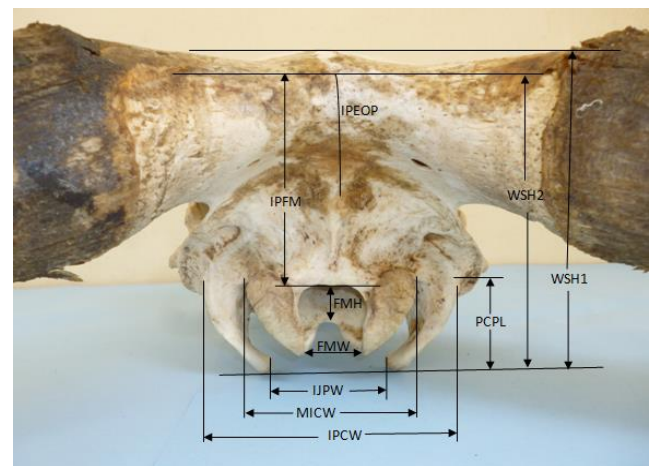


Figure 4: Measurements of the Kuri cattle skull without mandible (Parieto-occipital view) showing Intercornual protuberance to external occipital protuberance (IPEOP), Intercornual Protuberance to Foramen magnum (IPFM), Foramen magnum height (FMH), Foramen magnum width (FMW), Maximum intercondylar width (MICW), Interjugular process width (IJPW), Paracondylar process length (PCPL), Interparacondylar width (IPCW), Whole skull height 1 (WSH1), and Whole skull height 2 (WSH2).

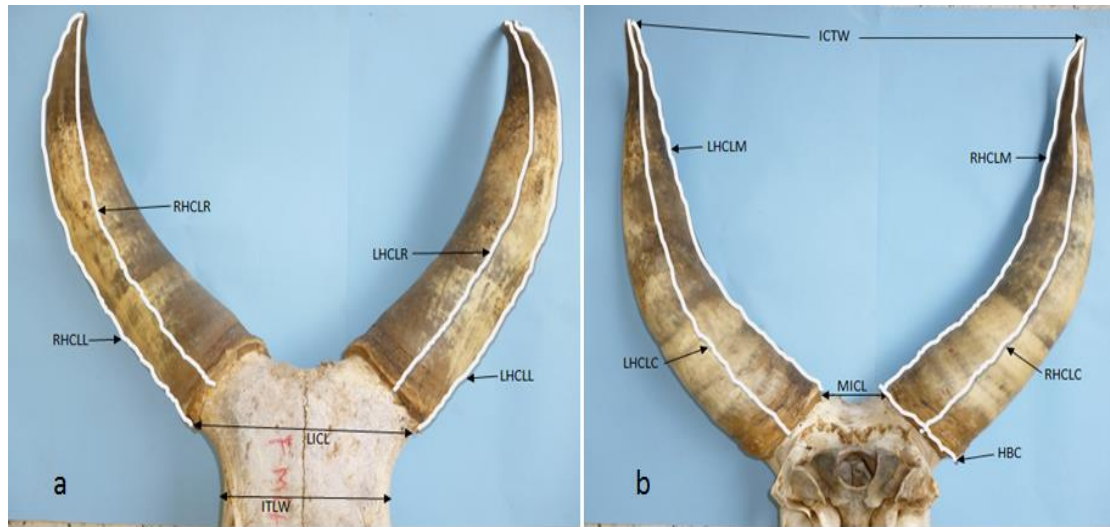

Figure 5: Measurements of the Kuri cattle skull (a. fronto-cornual and b. occipito-cornual view) showing a; Lateral intercornual length (LICAL), Right horn curvature length rostral (RHCLR), Left horn curvature length rostral (LHCLR), Right horn curvature length lateral (RHCLL), Left horn curvature length lateral (LHCLL), Intertemporal line width (ITLW). b; Medial intercornual length (MICL), Left horn curvature length caudal (LHCLC), Right horn curvature length caudal (RHCLC), Left horn curvature length medial (LHCLM), Right horn curvature length medial (RHCLM), Intercornual tip width (ICTW), and Horn base circumference (HBC).

DISCUSSION

To the best of our knowledge, this is the most comprehensive report in literature on the osteometry of skull of Kuri cattle. A total of 59 craniometric parameters were taken, and only 6 indices showed significant differences between the sexes. The result of this study revealed that the male Kuri cattle had significantly wider neurocranium (ISRSOF, ISLSOF, LICAL and ITLW) with non-significant wider viscerocranial width (IMCL and NW). The differences observed on the neurocranial width could be sexual dimorphism. Sexual dimorphism was reported in neurocranial width by Kobrynczuk *et al.* (2008) in "European bison" (*Bison bonasus bonasus*), but was not significant in the Camel (Yahaya *et al.*, 2012b). The horn base circumference (HBC) value in this study is higher in the male, depicting that the HBC influenced the size of the lateral intercornual length (LICAL) or vice versa.

All indices taken on the ventral aspect did not show any significant difference. The Choana length (ChL) is longer in the male, however, the hard palate length (HPL) value is higher in the female. This is further supported by higher value of the viscerocranial length (VCrL) of the female, indicating that the female Kuri cattle had longer viscerocranial length than the male. Insignificant higher palatal length values were reported in the female *Equus przewalskii f. caballus* (Early Medieval horses) by Pasicka *et al.* (2012) and in goats (Olopade and Onwuka 2005). However, Yahaya *et al.* (2012b) reported insignificantly high palatal length for the male one humped camel. Conversely, the hard palate was insignificantly wider at the intermolar region in the male Kuri cattle, which also conforms to the work of Pasicka *et al.* (2012), and

Yahaya *et al.* (2012b) as indicated above, but Olopade and Onwuka (2005) reported higher palatal width values in the female in West African Dwarf goat in Nigeria. The interfrontal suture (Neurocranium) length (IFSL) value is higher in the male; moreover, the overall skull length (INL) is higher in the male Kuri cattle as compared to the female. This is similar to what was reported in Early Medieval horses by Pasicka *et al.* (2012), in one humped camel (Yahaya *et al.* 2012b) and in lowland European bison (Kobrynczuk *et al.* 2008)

On the parieto-occipital aspect, only the base width between the lateral edges of the two occipital condyles i.e. maximum intercondylar width (MICW) showed significantly high value in the male Kuri cattle. This difference could be as a result thickness of the bases of the occipital condyle since the foramen magnum width value is higher in the female Kuri cattle. The foramen magnum height (FMH) and Paracondylar (jugular) process length (PCPL) were insignificantly higher in the female. Conversely, these values are higher in the young male one hump camel as compared to its female counterpart in Nigeria (Yahaya *et al.* 2012b). However, according to Samuel (2016) the foramen magnum height value is higher in the female, but wider foramen magnum width in the male *Procyonoides cancrivorus* (African giant Rat).

Out of the six indices that showed significant sex dimorphism (Table 5), only MICW showed sex dimorphism at two age groups; the young and middle-age groups. HBC and ISRSOF present sex dimorphism only at the middle-age group, while ISLSOF showed sexual dimorphism only on the cumulative value (n=15 for each sex) but not at any specific age group. ISFSOF and ISLSOF values are clinically important in locating the supraorbital foramen to track supraorbital

nerve in clinical procedures such as dehorning and trephination of frontal sinus. LICL and ITLW values showed significant sex dimorphism at $p < 0.01$ in the middle-age group with the male having higher values than the female. The aged group did not indicate any parameter with significant difference between the sexes.

In conclusion, the middle-age Kuri cattle (3-5 years old) have the most sexually dimorphic osteometric landmarks in the skull with the male having higher values than the female. This data will be useful for anatomical, developmental, anthropological, forensic and clinical studies, and forms bases for comparison with other breeds of cattle.

REFERENCES

- Bornholdt, R., Oliveira L. R., Fabian M. E. (2008). Sexual size dimorphism in myotis nigericans (Schinz, 1821) (Chiroptera: Vespertilionidae) from south Brazil. *Braz. J. Biol.* 68: 897-904.
- Epstein, H. (1971). The Origin of the Domestic Animals of Africa. Vols. 1 and 2. New York. Publ. Africana, pp 670.
- Gambo, B. G., Yahaya A., Femi-Akinlosotu O. Olopade J. O. (2015a). Investigation into dental abnormalities in Kuri cattle. *Sahel Journal of Veterinary Science*, Vol. 14(1): 1-5.
- Gambo, B. G., Yahaya A., Girgiri I. A., Olopade j. O. (2015b). Morphometric Studies of the mandibular and maxillofacial regions of the Kuri Cattle and the Implications in regional anaesthesia. *Folia Morphologica*. Vol. 74 (2) pp 183-187.
- Gambo, B. G., Yahaya A., Olopade J. O. (2016). Morphological Studies of the Facial Tuberoses and Infraorbital, Supraorbital and Mental Foramina in Kuri Cattle. *Global Veterinaria* Vol. 17(2):99-104.
- Kobrynczuk, F., Krasinska, M., Szara, T. (2008). Sexual dimorphism in skulls of the lowland European bison, *Bison bonasus bonasus*. *Ann. Zool. Fennici*. Vol. 45. pp 335-340.
- Malbrant, R., Receveur, P., Sabin, R. (1947a). Le boeuf du lac Tchad. *Rev. Elev. Med. Vet. Pays trop.* 1(1), 37-42.
- Malbrant, R., Receveur, P., Sabin, R. (1947b). Le boeuf du lac Tchad. *Rev. Elev. Med. Vet. Pays trop.* 1, 109.
- Mazak, J. H. (2004). On the sexual dimorphism in the the skull of the tiger (*Panthera tigris*). *Mammalian Biol.* Pp. 69: 392-400.
- Olopade, J. O. and Onwuka, S. K. (2005). Some Aspect of the Clinical Anatomy of the Mandibular and Maxillofacial Regions of West African Dwarf Goat in Nigeria. *International Journal of Morphology* 23: 33-36.
- Pasicka, E., Chrszcz A., Janeczek M. and Mucha A. (2012). Craniometric analysis of Early Medieval horses *Equus przewalskii f. caballus* from chosen areas in Poland. *Turkish Journal of Veterinary ad Animal science*. Vol. 36(6). pp 688-697.
- Pasquini, C. (1982). Atlas of Bovine Anatomy, Sudz Publishing Eureka, California. pp 60-62.
- Queval, R., Petit, J. P., Tacher, G., Provost, A., Pagot, J. (1971). Le Kouri. race bovine du lac Tchad. I, Introduction generale a son etude zootechnique et biochimique: Origins et ecologie de la race. *Rev. Elev. Med. Vet. Pays trop.* 24(4), 667-687.
- Samuel, M. O. (2016). Quantitative morphologic, craniodental and maxillofacial analytic studies on the head and cranium of *Procyonoides cancrivorous*. Ph.D. Thesis. Department of Veterinary Anatomy, University of Ibadan, Nigeria.
- Tawah, C. L., Rege, J. E. O. and Aboagye G. S (1997). A Close Look at a Rare African Breed-the Kuri Cattle of Lake Chad Basin: Origin, Distribution, Production and Adaptive Characteristics. *South African Journal of Animal Science*. 27(2), 31-40.
- Yahaya, A., Olopade J. O., Kwari H. D. Wiam I. M. (2012a). Osteometry of the skull of one-humped camels. Part I: Immature Camels. *Italian Journal of Anatomy and Embryology*. 117: 23-33.
- Yahaya, A., Olopade J. O., Kwari H. D. Wiam I. M. (2012b). Investigation of the Osteometry of the skull of the one-humped camels. Part II: sex dimorphism and geographical variations in adults. *Italian Journal of Anatomy and Embryology*. 117: 34-44.