



Arch. Bas. App. Med.13 (2025) 11-13
www.archivesbamui.com
www.ojshostng.com/index.php/abam

Case Report

Multiple Skull Anomalies in a Nigerian Adult Male: Case Report

*Oyedun, O.S. and Owoeye, O.

Department of Anatomy, College of Medicine, University of Ibadan, Ibadan, Nigeria

Accepted: February 21, 2025.

Abstract

The skull, the most complicated bony structure in the body, is made up of twenty-two bony pieces that are approximated at the sutures. Establishment of accessory ossification centers in the sutures result in the formation of Inca and Wormian bones. This is a case report detailing the occurrence of an unusual bone (inca bone) in posterior skull with asymmetry in size and shape of the oval and carotid foramina at the base of the skull. Following bone maceration of dissected cadavers in the Department of Anatomy, University of Ibadan, Nigeria, we observed multiple anomalies in an adult male Nigerian skull. The skull presented with an Inca bone, complete ostosis of sagittal & lambdoidal sutures, right infraorbital fissure, left infraorbital foramen with adjoining canal, bilateral supraorbital notches, large non-symmetrical right foramen ovale and carotid foramen, thickened left superior temporal line and straightening of the mid 1/3rd of the coronal suture.

Awareness of the existence of Inca bones, complete ostosis of sagittal and lambdoidal sutures and thickened superior temporal lines by radiologists is important in order to avoid misdiagnosing them for fractures. The occurrence of inca bones, completely fused sutures and thickened cranial bone markings pose problems to surgical access to the cranial cavity during neurosurgical procedures. However, they can be useful tools in anthropometric and forensic identification of human beings.

Key Words: Skull, Anomalies, Ostosis, Inca, Wormian, Bone

INTRODUCTION

The skull, the most complicated bony structure in the human body, is made up of twenty-two bony pieces that are approximated at the sutures. These individual bony pieces are formed from primary ossification centers within them. Additional ossification centers are sometimes established in the sutures resulting in the formation of Wormian and Inca bones (Pendergrass *et al.*, 1956). Inca bones earned its name from the high occurrence of these bones in mummified and present-day skulls of the Inca people of Peru Republic. Inca bones are inter-parietal bones resulting from accessory ossification centers in the occipital region (Standing, 2008). It is limited superiorly and inferiorly by lambdoidal and transverse occipital (medosal) sutures respectively (Standing, 2008).

The sagittal suture runs along the cranial median plane and bifurcates, at the occipital region, into the lambdoidal suture. The sagittal suture is limited anteriorly by the coronal suture which separates the frontal bone from the parietal bones. The sagittal, coronal and lambdoidal sutures are made up of a suture complex comprising the dural mater, calvarial bone plate, suture mesenchyme and pericranium (Slater *et al.*, 2008). Studies have shown the cranial sutures to fuse with advancing age (Gorea *et al.*, 2004) and in pathological conditions. Premature fusion of the cranial sutures in fetus is usually associated with cranial malformations and it is termed craniosynostosis. It has been demonstrated that suture elements fuse from deep to superficial (Standing, 2008).

The middle cranial fossa lodges four foramina (superior orbital fissure, foramen rotundum, foramen ovale and foramen spinosum) that are arranged in circular fashion and often referred to as crescent of foramen (Moore *et al.*, 2010). The foramen ovale, the largest of the crescent of foramen, has been shown to exhibit a high level of variability in shape and size (Shaikh and Kulkarni, 2014). It transmits the mandibular nerve, accessory meningeal artery, lesser petrosal nerve and emissary veins (Moore *et al.*, 2010). Knowledge of these variations is needed when assessing the cranial base through the transcuteaneous approach in neurosurgical management of trigeminal neuralgia (Kaplan *et al.*, 2007). The carotid foramen lies in the petrous part of temporal bone and it forms an entrance into the carotid canal. The main structure it transmits is the carotid artery (Moore *et al.*, 2010). The supra and infra orbital foramina are small openings that are closely related to orbit. They transmit the supra and infra orbital nerves and vessels respectively (Moore *et al.*, 2010).

The superior and inferior temporal lines are limiting structures that form the superior and posterior boundary of the temporal fossa (Moore *et al.*, 2010). Thickened temporal lines may give a false appearance of fracture on plain lateral skull radiographs. The aim of this case report is to detail the occurrence of an unusual bone (inca bone) in posterior skull and asymmetry in size and shape of oval and carotid foramina at the base of the skull.

CASE REPORT

*Author for Correspondence: Tel: +2347030059777

E-mail: drdayooyedun@yahoo.com;
oyedundayo@yahoo.com

Following bone maceration of dissected cadavers in the gross dissection laboratory of the department of Anatomy, University of Ibadan, Nigeria, we observed multiple anomalies in a male Nigerian skull (of unknown age). The skull presented with an interparietal bone (inca bone) in the occipital region (Fig 1). The bone was roughly pyramidal in shape and it measured 6.32 cm in height and 5.81 cm in maximum width. The bone was bounded by transverse occipital suture inferiorly and lambdoidal suture superiorly. The lambdoidal suture, together with the sagittal suture, was completely ossified in this skull (Fig 2). However, there was no accompanying scaphocephaly or any other cranial shape anomaly.

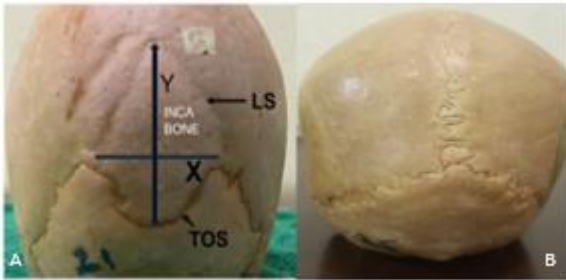


Fig 1A. Picture of the skull showing the inca bone bounded by the Lambdoidal suture (LS) and Transverse Occipital Suture (TOS). (Y-Height, X- Maximum width). 1B. Picture of the posterior aspect of a normal skull for comparison.



Fig 2. Picture of the skull showing ossification of the lambdoidal suture (LS) and Sagittal suture (SS).

We also observed distortion in the shape and size of some foramina in the index skull. The right infraorbital opening appeared as an aperture (fissure) instead of a foramen (Fig 3). The left infraorbital opening was big and round (foramen), and it had an adjoining canal attached to its inner border. The supraorbital foramen were absent bilaterally and replaced with supraorbital notches (Fig 3). The two parietal foramen appeared prominently large. The right foramen ovale and right carotid foramen appeared very large when compared with their left counterparts (Fig 4).

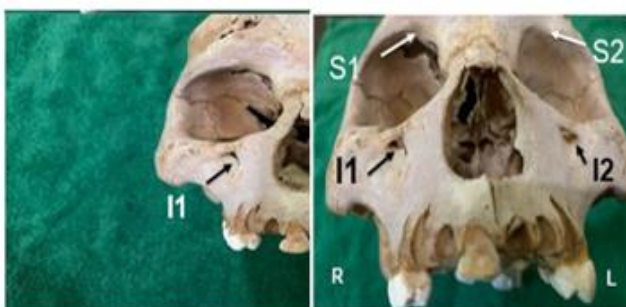


Fig 3.

Picture of the skull showing anomalous variations of the foramen related to the orbit. (Right Supraorbital groove- S1, Left Supraorbital groove-S2, Right Infraorbital fissure- I 1, Left Infraorbital foramen - I 2).

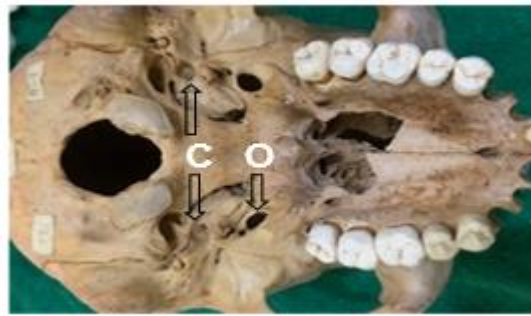

Fig 4. Picture of the skull showing discrepancy in the sizes of the right Foramen ovale (O) and right Carotid foramen (C) relative to those of the left.

The left superior temporal line was raised and thickened thus appearing as a ridge rather than a line (Fig 5). There was reduced convolution (straightening) of the mid 1/3rd portion of the coronal suture (Fig 5).

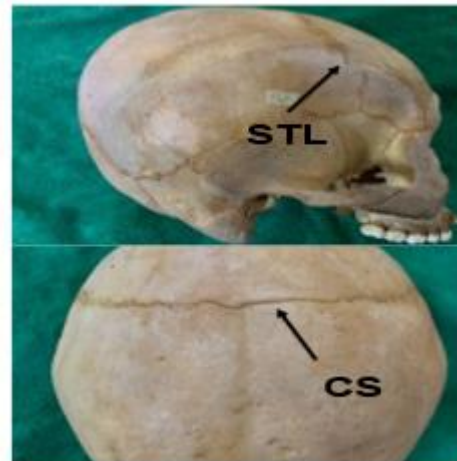


Fig 5. Picture of the skull showing thickening of the Superior temporal line and unfolding (straightening) of the coronal suture (Superior temporal line- STL, Coronal Suture-CS).

DISCUSSION

Inca bones are rare interparietal bones which exhibit geographical and ethnical variations in occurrence and morphology. Researchers have estimated the occurrence to be between 0.8%-15% in the various populations (Strivastava, 1992; Marathe *et al.*, 2010; Sibel, 2014; Yücel *et al.*,1998). The bone can exist in a single piece or can be fragmented into two (Bipartite) or three (Tripartite) by the longitudinal occipital suture. We observed an unfragmented inca bone, which differs from the bipartite type reported by Cirpan *et al.* (2014) and tripartite type reported by Gardner (2016).The shape of the inca bone, reported in this study, is pyramidal which is consistent with those described by Ibrahim (2020). Inca bones have also been reported to assume triangular, ovoid and irregular shapes (Das *et al.*, 2005).

Contrary to the previously reported cases, we observed an inca bone with co-existing complete osteosis of the sagittal

and lambdoidal sutures. Alves *et al.*, (2009), in a study on 88 dry human skulls, showed that fusion begins at the posterior end of the sagittal suture and progresses anteriorly. There are conflicting reports with respect to progression of sagittal suture osteosis with advancing age. While some studies support this hypothesis (Gorea *et al.*, 2004), others reject it (Alves *et al.*, 2009). This conflict renders the use of sutural ostosis in predicting the age of an individual, at time of death, unreliable. Complete ostosis of cranial suture, especially when it occurs in early fetal life, presents with skull shape anomalies. Scaphocephaly has been reported to be associated with early fusion of sagittal sutures (Weinzweig *et al.*, 2002). The skull presented in this index skull however had no shape anomaly in spite of complete ostosis of its sagittal suture. Infraorbital foramen transmits infraorbital nerve, artery and vein. The occurrence of infraorbital fissure instead of foramen on the left side results in elongation of the transverse dimension of the aperture. We opined that the infraorbital fissure, in view of its elongated space, is spatially enabled to transmit more neurovascular structures. Unfortunately, this predisposes the structures to compression because of the reduced vertical dimension. The canal attached to the right infraorbital foramen may confer added protection to the transmitted neurovascular structures. The reverse is the case for the supraorbital opening (notch), which is devoid of supporting inferior border and as a result exposing the structures.

The complexity of a cranial suture is believed to be influenced by both intrinsic and extrinsic factors (Opperman, 2000; Sabini and Elkowitz, 2006). Extrinsic factors such as tensile force, strain from expanding brain and active muscle demand have been shown to affect suture complexity and patency (Sabini and Elkowitz, 2006). Sabini and Elkowitz further demonstrated that the more the tensile force acting on a suture, the more the complexity and interdigitations. The simple, straightened, unfolded morphology observed in mid-1/3rd portion of the coronal suture in this case report may be due to low tensile force acting on it.

CONCLUSION

Multiple skull abnormalities were observed in this adult Nigerian male, including occurrence of an inca bone, size-asymmetry of Oval & Carotid foramen and shape-asymmetry of infraorbital foramen. Awareness of these anomalies is important in preventing misinterpretation of skull X-ray and complications during neurosurgical procedures. The occurrence of Inca bones serves as useful tool in anthropometric and forensic identification of human beings.

REFERENCES

- Alves, J. C., Wafae, G. C., Coelho, D. D., Wafae, N., Coelho, V. D., Pereira, E., Ruiz, C.R. 2009. Sagittal suture of the human cranium and the time of closing. *Int. J. Morphol.* 27:2 ;469-473.
- Cirpan S., Aksu F., and Mas N.G. 2014. Inca Bone in Human Skulls of the West Anatolian Population. *International Journal of Morphology.* 32:1 ;275-278.
- Das, Srijit, Suri, Rajesh, Kapur, Vijay . 2005. Anatomical observations of Os Inca and associated Cranial deformities. *Folia Morphol.* 64: 2; 118-121.
- Gardner. S. 2016. A Human Skull with a Tripartite Inca Bone: A Case Report. *Forensic Medicine and Anatomy Research.* 4 :3; 37-39.
- Gorea R.K., Singh P., Oberoi S.S., Kapila A.K. 2004. Age estimation in old individuals by CT scan of skull. *Journal of Indian Academy of Forensic Medicine.* 26 :1;10-13.
- Ibrahim.I. 2022. Anatomical variations of inca bone in adult human Egyptian skulls. *International Journal of Approximate Reasoning.* 8:7271-7276.
- Kaplan, M, Erol, F. S., Ozveren, M. F., Topsakal, C., Sam, B., Tekdemir, I. 2007. Review of complications due to foramen ovale puncture. *J. Clin. Neurosci.*, 14:6 ;563-568.
- Marathe, R., Yogesh, A., Pandit, S., Joshi, M., & Trivedi, G. 2010. Inca - interparietal bones in neurocranium of human skulls in central India. *J. Neurosci. Rural Pract.*, 1:1;14-6
- Moore, K L., Agur, M.R. and Dalley, A. F. 2010. Clinically oriented Anatomy. 6th Edition, Lippincott Williams & Wilkins, a Wolters Kluwer business. Baltimore (Philadelphia) 826-827.
- Opperman L.A. 2000. Cranial sutures as intramembranous bone growth sites. *Dev Dyn*, 219:4;472-485.
- Pendergrass E.P., Schaeffer J.P., Hodes P.J. 1956. The head and neck in Roentgen diagnosis. Charles C. Thomas, Springfield 211-218.
- Sabini R.C., Elkowitz D.E .2006. Significance of differences in Patency among cranial sutures. *J. Am. Osteopath Assoc.* 106:10;600-604.
- Shaikh V.G., Kulkarni P.R. 2014. A study of morphology, morphometry, symmetry and development of external opening of carotid canal with comparison in male, female and foetus. *Int. J. Anat. Res.* 2:797-805.
- Slater B.J., Kwan M.D., Gupta D.M. 2008. Dissecting the influence of regional dura mater on cranial suture biology. *Plast. Reconstr. Surg.* 122:77-84.
- Srivastava, H.C. 1992. Ossification of the Membranous Portion of the Squamous Part of the Occipital Bone in Man. *Journal of Anatomy.* 180, 219-224.
- Standring, S. 2008. Gray's Anatomy: The Anatomical Basis of Clinical Practice. 40th Edition, Churchill Livingstone Elsevier, London. 603-605.
- Weinzweig J, Baker S.B., Whitaker L.A., Sutton L.N., Bartlett S.P. 2002. Delayed cranial vault reconstruction for sagittal synostosis in older children: an algorithm for tailoring the reconstructive approach to the craniofacial deformity. *Plast. Reconstr. Surg.* 110:2;397-408.
- Yücel F, Egilmez H and Akgün Z .1998. A Study on the Interparietal Bone in Man. *Tr. J. of Medical Sciences.* 28:505-509.